

# Platelet-Rich Plasma Injection for Partial Patellar Tendon Tear in a High School Athlete: A Case Presentation

Kelly L. Scollon-Grieve, MD, Gerard A. Malanga, MD

## INTRODUCTION

Patellar tendinosis, also referred to as jumper's knee, is most commonly seen in elite athletes who participate in sports that involve jumping and directional changes. The prevalence has been estimated to be as high as 35%-40% in elite basketball players [1]. Histopathologic and biochemical evidence has indicated that the underlying pathology of tendinopathy is not inflammatory tendonitis but rather degenerative tendinosis [2]. Tensile overloading may cause microtearing of the tendon fibers followed by a focal degeneration. The onset is usually insidious and may relate to an increase in training intensity. Jumper's knee is often refractory to currently available treatments, including relative rest, exercise (with a focus on repetitive eccentric loading), bracing, nonsteroidal anti-inflammatory drugs (NSAIDs), ultrasound, cryotherapy, friction massage, prolotherapy, corticosteroid injection, extracorporeal shock wave therapy, aprotinin injection, surgical decompression and resection, and open stimulation techniques. An asymptomatic tendinosis may precede an acute patellar tendon tear [2-4]. A complete rupture of the patellar tendon is often treated with early surgical intervention followed by a protracted rehabilitation course [5]. This course of treatment may not always allow for a return to competitive sport participation.

Autologous blood injection has been reported to show promise in the treatment of tendinopathy [3]. There is a paucity of literature concerning the incidence and treatment outcomes of patellar injuries in adolescent athletes and the use of platelet-rich plasma (PRP) therapy for such conditions. This article provides a case presentation of the management of an adolescent athlete with a large partial patellar tendon tear through the use of ultrasound-guided injection of PRP.

## CASE PRESENTATION

A healthy 18-year-old competitive high school lacrosse player presented to a local sports medicine physician with pain that began with a few episodes of sharp right-sided knee pain while playing a basketball game in the off-season. During one specific game in the off-season, he had severe anterior right knee pain as he went from a run to an abrupt stop. He continued to play with pain. The pain was localized to the proximal portion of the patellar tendon; it was described as sharp and was rated as an 8/10 on an analog pain scale. The symptoms were precipitated by running and squatting and were relieved with rest and avoidance of aggravating activities. The patient initially was treated for patellar tendonitis and patellofemoral pain. However, his pain persisted for nearly a year. He had only minimal improvement with conservative treatment, which included NSAIDs, a patellar tendon orthosis, and physical therapy. He underwent radiographic imaging of both knees, which showed no acute fractures, avulsions, or dislocations. Magnetic resonance imaging of the right knee revealed a near full-thickness tear of the right patellar tendon (Figures 1 and 2).

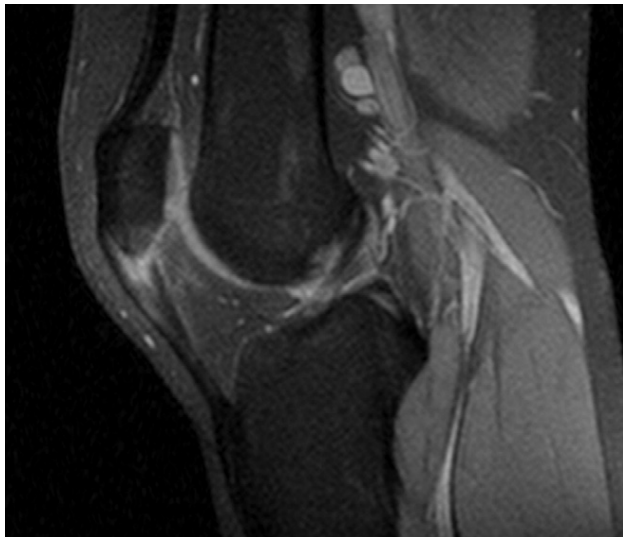
The patient was then referred to us for possible PRP injection because of his persistent pain and the dramatic findings on magnetic resonance imaging. At the time of his initial evaluation, he had persistent anterior knee pain with any running and jumping activity, and minimal pain with daily ambulation. On physical examination, he was noted to have a Q-angle of less than 15° and mild overpronation of his feet. No effusion was present, and he displayed full active and passive range of motion of his knee, with anterior knee pain on full

**K.L.S.-G.** Department of Physical Medicine and Rehabilitation, University of Medicine and Dentistry of New Jersey, New Jersey Medical School, 30 Bergen St, ADMC 101, Room 101, Newark, NJ 07101. Address correspondence to K.L.S.-G.; e-mail: [scollok1@umdnj.edu](mailto:scollok1@umdnj.edu). Disclosure: nothing to disclose

**G.A.M.** New Jersey Sports Medicine, Summit, NJ  
Disclosure: nothing to disclose

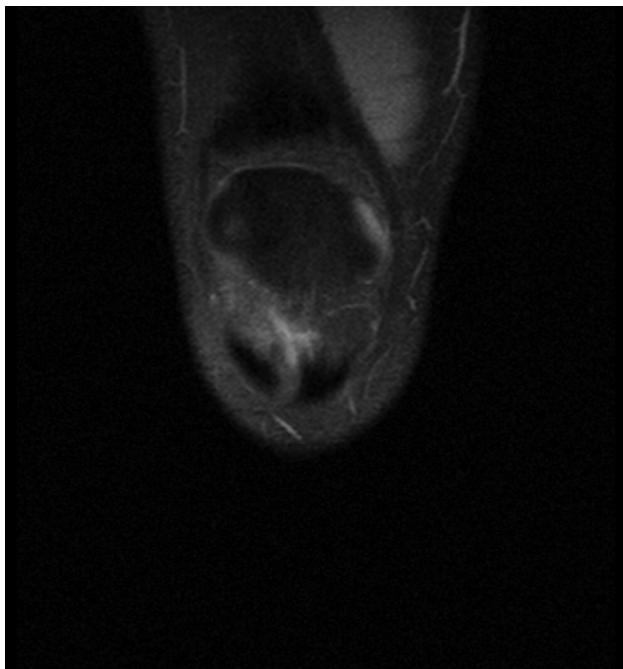
Disclosure Key can be found on the Table of Contents and at [www.pmrjournal.org](http://www.pmrjournal.org)

Submitted for publication May 12, 2010; accepted November 29, 2010.

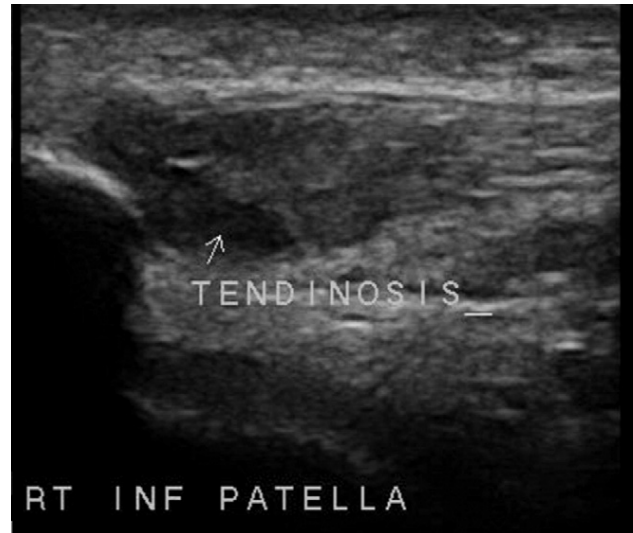

**Figure 1.** Sagittal view with increased signal in the proximal patellar tendon on magnetic resonance imaging.

flexion. He had focal tenderness to palpation over the inferior pole of the patella on the right. Palpation about the patella revealed no tenderness. Results of patellar compression and apprehension tests were negative. His pain was localized to the patellar tendon. Results of Lachman, anterior and posterior drawer, valgus and varus stress, and McMurray tests



**Figure 2.** Coronal view of a proximal patellar tendon tear on magnetic resonance imaging.

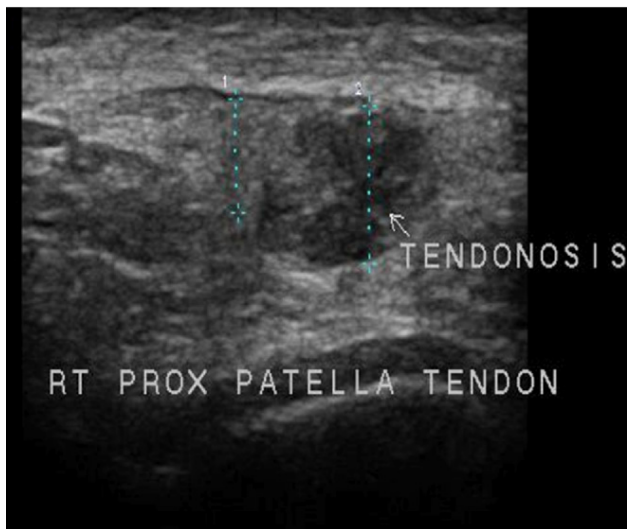


**Figure 3.** Long-axis view of a right partial patellar tendon tear on ultrasound imaging.

were all negative [6]. He had normal and symmetric strength on manual muscle testing, including his quadriceps. His anterior knee pain was reproduced with a deep knee bend.

At his initial visit, a dynamic musculoskeletal ultrasound examination was performed with a GE LOGIQ e ultrasound system (GE Healthcare, Waukesha, WI) with a 12L-RS high-frequency linear transducer (5-13 MHz). The patellar tendon was evaluated on the long axis and the short axis by using the inferior pole of the patella and the tibial tuberosity as landmarks for identification of the patellar tendon. The ultrasound examination revealed a large hypoechoic area in the proximal medial portion of the right patellar tendon consistent with a partial to a near full-thickness tear of the proximal medial patellar tendon (Figures 3 and 4). The quadriceps tendon and muscle were intact, with no evidence of tearing or tendinosis. The treatment options were explained to the patient and his father, and all were in agreement that the best option was PRP injection into the right patellar tendon defect. The patient was instructed to refrain from taking NSAIDs and from running, jumping, or performing lower-extremity strengthening exercises.

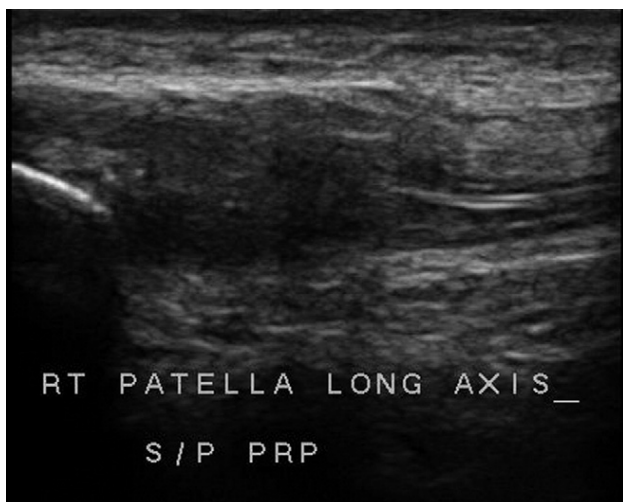
At the following visit, standard technique and a 19-gauge butterfly needle via antecubital access were used to draw about 60 mL of the patient's blood, which then was centrifuged for 15 minutes in an Arteriocyte machine (Arteriocyte Inc, Cleveland, OH) to make a preparation of PRP. The area was cleansed with alcohol, and skin wheals with 3 mL of 1% lidocaine were made at the entry site. Next, 5 mL of PRP was injected, with a peppering technique, into the tendon defect under ultrasound guidance with use of a 22-gauge 1.5-inch needle. Once again, the patient was instructed to refrain from taking NSAIDs and from using ice. After the procedure, he



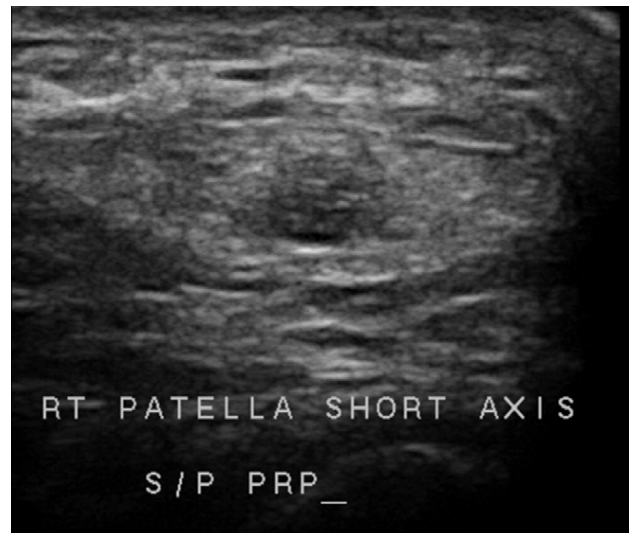**Figure 4.** Short-axis view of a right patellar tendon defect.

was instructed to rest for 1 week (ie, only walking normal distances for daily activities). He refrained from running, jumping, or doing resistance training for 4 weeks. Progressive open chain resistance training was started at 4 weeks, stressing low-weight, high-repetition exercises and lower-extremity stretches. At 6 weeks the patient started closed chain exercises, including squats and eccentric training as tolerated. It was recommended that he take a multivitamin, zinc (50 mg daily), and vitamin C (500 mg daily), and he began this regimen immediately after the injection was performed.

At a 1-month follow-up, the patient reported an estimated 90% clinical improvement in function (based on a functional



**Figure 5.** Long-axis view of a healing partial patellar tendon tear after a PRP injection.



**Figure 6.** Short axis view of a healing defect after a PRP injection.

analog scale) and a complete resolution of pain. Ultrasound scanning was again performed by using the same landmarks of the inferior pole of the patella and the tibial tuberosity to locate the patellar tendon where the initial lesion was noted. This area demonstrated improved echogenicity, within 90% of the prior defect located in the superior/medial aspect of the right patellar tendon (Figures 5 and 6). Two months after receiving the injection, he returned to full activity and is currently playing lacrosse at the collegiate level without pain or limitation.

## DISCUSSION

The symptoms of a partial patellar tendon tear in a young athlete may be difficult to differentiate from more common knee pathology, such as patellofemoral syndrome, Sinding-Larsen-Johansson apophysitis, patellar sleeve fracture, or fat pad impingement, and they may coexist [4]. A complete or partial patellar tendon tear is usually associated with a sudden eccentric contraction of the quadriceps muscle, which may occur when an athlete jumps. The symptoms of a complete tear are more easily identified than those of a partial tear. When a complete tear occurs, the athlete often describes a sensation of tearing with a sudden onset of pain over the patellar tendon and an inability to stand. On examination, a loss of fullness in the anterior knee may be noted due to a retracted patellar tendon and an inability to initiate knee extension, because the knee extensor mechanism is disrupted [5]. With a partial tear, the action of the extensor mechanism is not compromised; therefore the athlete will be able to initiate knee extension. The clinical features of a partial patellar tendon tear are similar to those of patellar tendinosis and include the following: anterior or inferior

knee pain that is aggravated by jumping, prolonged sitting, and when ascending and descending stairs; and tenderness to palpation over the inferior pole of the patella [4,5].

The treatment of a partial patellar tendon tear is similar to that of tendinosis and can pose a challenge to the physician. The mainstay of treatment remains conservative, nonoperative treatment that focuses on relative rest, stretching, eccentric quadriceps strengthening, and modalities. Eccentric exercise has been shown to be successful in treatment of Achilles tendinopathy [7]. However, scientific evidence to assess the efficacy of these treatments for patellar tendinopathy is sparse [2,8,9]. In a study by Cannell et al [10], athletes with patellar tendinopathy who completed a 12-week program of either eccentric drop squats or leg extensions/curls had a 57% and 36% improvement in pain, respectively. Young et al [11] demonstrated greater clinical improvement in volleyball players with patellar tendinopathy who performed an eccentric decline single-leg squat protocol versus those who participated in a traditional eccentric single-leg squat protocol. Our patient participated in a traditional eccentric rehabilitation protocol, and that type of conservative treatment was unsuccessful; therefore, he was found to be a good candidate for PRP therapy.

It is not uncommon for patients to have prolonged courses of pain and disability with conservative management, which affects their daily activities and, in athletes in particular, their ability to participate in sports [10]. Historically, when conservative management has failed, surgery is the next step. Surgical intervention is invasive, requires a long rehabilitation period, and has not been proven to be highly efficacious in these types of injuries [2,10].

In an effort to enhance recovery from tendon injuries and avoid surgical procedures, PRP therapy has become increasingly popular in the sports medicine practice. Autologous PRP therapy was first used in 1987 by Ferrari et al to avoid excessive transfusion of blood products after an open-heart surgery [12]. Since then, the safe use of PRP has been documented in the fields of orthopedics, sports medicine, maxillofacial surgery, otolaryngology, ophthalmology, wound healing, and cosmetic and cardiothoracic surgery. Blood contains plasma, red blood cells, white blood cells, and platelets. Plasma, the liquid component of blood, acts as a transporter for cells. It contains fibrinogen, which is a protein that attracts platelets to a wound site to form a clot. Platelets are the smallest of the blood cells and are the first cells to reach a site of injury. They contain more than 30 bioactive proteins that play a role in hemostasis, construction of new connective tissue, and revascularization [13,14].

PRP is injected directly into the damaged tissue, with the goal of optimizing wound healing through delivery of growth factors. The growth factors found in platelets are stored in the  $\alpha$ -granule. These growth factors include the following: platelet-derived growth factor, vascular endothelial growth factor, transforming growth factor- $\beta$ 1, epidermal growth factor,

basic fibroblast growth factor, and insulin-like growth factor-1. It is thought that the advantage of using PRP rather than injecting purified individual growth factors is that PRP contains many growth factors present in physiological proportions, thereby allowing a natural balance of proliferative and inhibitory effects. PRP is thought to be an easy, cost-effective method to deliver a high concentration of growth factors to a site of injury [14].

The use of PRP therapy for tendon injuries is based on the fact that tendons have a low metabolic rate that leads to slow healing after injury. It has been shown that injection of PRP increases the proliferation of tenocytes and stimulates them to produce growth factors such as vascular endothelial growth factor and hepatocyte growth factor, which promote angiogenesis and increase tendon-healing capabilities. Because hepatocyte growth factor is an antifibrotic agent, it also may help to reduce scar formation around the tendon tissues [8].

Few controlled clinical studies with a high level of medical evidence have been published to support the potential benefits of PRP. However, numerous case reports, small case series, and animal studies support its efficacy. Several animal studies have demonstrated a positive effect of PRP therapy on tendon healing. Aspenberg and Virchenko [15] injected PRP into transected Achilles tendons of rats and demonstrated a 30% increase in the strength and stiffness of the tendon callus after 1 week. de Vos et al [16] found no significant difference in patients with Achilles tendinopathy who were treated with eccentric exercises and PRP injection compared with those who were injected with saline solution. Kajikawa et al [17] found that, by injecting PRP into partially torn patellar tendons of mice, collagen synthesis was enhanced in the PRP group at 3 and 7 days after injection. In a small study by Filardo et al [18], there was statistically significant improvement in all scores after multiple PRP injections in patients with chronic refractory patellar tendinopathy, and a further improvement was noted 6 months after physical therapy was added.

## CONCLUSIONS

Patellar tendon tears in the adolescent athlete are uncommon and difficult to treat with conservative measures. Surgery is invasive and is used as a last resort in refractory cases that are unresponsive to conservative treatment with mixed results. There is a growing interest in and use of PRP to treat soft-tissue and sports-related injuries. It is a safe and promising alternative for patients with injuries that have been refractory to conservative treatment. In the case presented, ultrasound-guided injection of PRP into a patellar tendon defect resulted in healing of the defect and allowed this young athlete with a significant patellar tendon tear to return to competitive collegiate lacrosse participation.

## REFERENCES

1. Khan KM, Maffulli N, Coleman BD, Cook JL, Taunton JE. Patellar tendinopathy: Some aspects of basic science and clinical management. *Br J Sports Med* 1998;32:346-355.
2. Cook JL, Khan KM. What is the most appropriate treatment for patellar tendinopathy? In: MacAuley D, Best T, eds. *Evidence Based Sports Medicine*, 2nd ed. Malden, MA: Blackwell Publishing; 2007: 476-490.
3. Creaney L, Hamilton B. Growth factor delivery methods in the management of sports injuries: The state of play. *Br J Sports Med* 2008;42:314-320.
4. Warden SJ, Brukner P. Patellar tendinopathy. *Clin Sports Med* 2003; 22:743-759.
5. Brukner P, Khan K. *Clinical Sports Medicine*, 3rd ed. Sydney, Australia: McGraw-Hill; 2007.
6. Malanga GA, Nadler S. *Musculoskeletal Physical Examination: An Evidence-based Approach*. Philadelphia, PA: Mosby; 2006.
7. Alfredson H, Pietilä T, Jonsson P, Lorentzon R. Heavy-load eccentric calf muscle training for the treatment of chronic Achilles tendinosis. *Am J Sports Med* 1998;26:360-366.
8. Alsousou J, Thompson M, Hulley P, Noble A, Willett K. The biology of platelet-rich plasma and its application in trauma and orthopaedic surgery. *J Bone Joint Surg Br* 2009;91-B:987-996.
9. Foster TE, Puskas BL, Mandel BR, Gerhardt MB, Rodeo SA. Platelet-rich plasma: From basic science to clinical applications. *Am J Sports Med* 2009;37:2259-2272.
10. Cannell LJ, Taunton JE, Clement DB, Smith C, Khan KM. A randomized clinical trial of the efficacy of drop squats or leg extension or leg curl exercises to treat clinically diagnosed jumper's knee in athletes: Pilot study. *Br J Sports Med* 2001;35:60-64.
11. Young MA, Cook JL, Purdam CR, Kiss ZS, Alfredson H. Eccentric decline squat protocol offers superior results at 12 months compared with traditional eccentric protocol for patellar tendinopathy in volleyball players. *Br J Sports Med* 2005;39:102-105.
12. Ferrari M, Zia S, Valbonesi M. A new technique for hemodilution, preparation of autologous platelet-rich plasma and intraoperative blood salvage in cardiac surgery. *Int J Artif Organs* 1987;10:47-50.
13. Sampson S, Gerhardt M, Mandelbaum B. Platelet rich plasma injection grafts for musculoskeletal injuries: A review. *Curr Rev Musculoskeletal Med* 2008;1:165-174.
14. Sánchez M, Anitua E, Orive G, Mujika I, Andia I. Platelet-rich therapies in the treatment of orthopedic sports injuries. *Sports Med* 2009;39: 345-354.
15. Aspenberg P, Virchenko O. Platelet concentrate injection improves Achilles tendon repair in rats. *Acta Orthop Scand* 2004;75:93-99.
16. de Vos RJ, Weir A, van Schie HT, et al. Platelet-rich plasma injection for chronic Achilles tendinopathy: A randomized controlled trial. *JAMA* 2010;303:144-149.
17. Kajikawa Y, Morihara T, Sakamoto H, et al. Platelet-rich plasma enhances the initial mobilization of circulation-derived cells for tendon healing. *J Cell Physiol* 2008;215:837-845.
18. Filardo G, Kon E, Della Villa S, Vincentelli F, Fornasari PM, Marcacci M. Use of platelet-rich plasma for the treatment of refractory jumper's knee. *Int Orthop* 2010;34:909-915.